

ANIL AGRAWAL'S INTERNET JOURNAL OF FORENSIC MEDICINE AND TOXICOLOGY

Ref –Mittal P, Sharma B. Bricks Shedding Blood In The Darkness Of Night: Story of a Mortal Homicide Uncovered At Autopsy (Skeleton Keys to Homicide). *Anil Aggrawal's Internet Journal of Forensic Medicine and Toxicology* [serial online], 2021; Vol. 22, No. 2 (July - December 2021): about 9p. Available from: http://anilaggrawal.com/ij/vol_022_no_002/papers/paper004.html. Published as Epub Ahead: May 23, 2021.

Access the journal at - <http://anilaggrawal.com>

Case Report

BRICKS SHEDDING BLOOD IN THE DARKNESS OF NIGHT: STORY OF A MORTAL HOMICIDE UNCOVERED AT AUTOPSY

(Skeleton Keys to Homicide)

By

PAWAN MITTAL*, BALRAJ SHARMA

Department of Forensic Medicine, Bhagat Phool Singh Govt. Medical College and Hospital, Khanpur Kalan-131305, Sonapat, Haryana, India

*Corresponding author:

E-mail ID: drmittalpawan@gmail.com

Contact No. +91-9996031331

Cite as: Mittal P, Sharma B. Bricks Shedding Blood in the Darkness of Night: Story of a Mortal Homicide Uncovered at Autopsy (Skeleton Keys to Homicide). *Anil Agg Internet J Forensic Med Toxicol* (July-Dec) 2021;22(2):about 9p.

ABSTRACT

A medicolegal autopsy provides critical evidence to the cause and manner of death, demography of victim, and nature of the crime committed. This task however becomes increasingly difficult if the bodies are decomposed or skeletonized, exposed to scavengers or different environmental conditions, that may introduce a variety of alterations in the physical remains. The main objective of the postmortem examination in such cases is to diagnose skeletal wounds along with an accurate interpretation of their mechanism; as this evidence may be the only clue to a potential homicide. Thereby, the whole skeletal analysis is focused towards discovery of acute injuries and to differentiate them, simultaneously, from the postmortem modifications, as a misdiagnosis may initiate an unnecessary or even fake criminal investigation. Furthermore, in criminal circumstances, especially involving clandestine situations, it is not uncommon for a corpse to remain undiscovered for an indefinite time period thereby causing loss of medicolegally significant findings. The present case deals with the mummified and skeletonized body of a young male, which was purportedly found within an under-construction building that was almost in ruins and located at an abandoned place. The autopsy discovered multiple depressed fractures over the skull, signifying lethal blows given to the head. A detailed analysis was further performed by maceration and processing of the skull through which a sound understanding of the mechanisms involved in blunt cranial trauma could be gained. The autopsy, in conjunction with the crime scene details, helped in uncovering the story of a homicide which was later corroborated with police investigations, as the alleged weapons along with the whole story came to the light of forensic doctors. The mechanism and manner of injuries along with the possible cause(s) of death are explained.

Key words: Skull fracture, Depressed, Autopsy, Homicide, Cause of death, Trauma, Crime

1. INTRODUCTION:

Every discovery of a corpse raises the question whether the body belongs to a victim of homicide or not. This task becomes increasingly difficult or even impossible if the corpse is badly altered and/or depicts advanced taphonomic alterations in the form of decomposition, skeletonization, animal scavenging, and/or bone fragmentation.¹ Despite these challenges, a careful analysis of skeletal remains may yield significant information regarding cause and manner of death.

Because perpetrators frequently attempt to conceal a homicide by disposing off the victim's body in different ways, a prolonged postmortem period may ensue between the time of death and corpse's discovery.² The discovery of violent injuries over the bones may provide initiation to a potential homicide investigation. A medicolegal autopsy is therefore performed to secure any available evidence that may confirm or rule out the possibility of a crime.

A skeletonized and mummified body of an unknown and unidentified young male individual was discovered within a dark room of a poorly constructed building that was almost in ruins and located at an abandoned place over a highway. A preliminary police investigation, alleging 'some disease process or insect bite' to be the cause of death, was refuted on the basis of postmortem findings that emerged with the discovery of multiple depressed skull fractures (DSFs), suffered from violent blows given to the head during an assault with some heavy/hard blunt object(s).

The accused were later traced who revealed the whole incident and disclosed the involved weapons that were later brought for forensic examination in order to correlate with the injuries and resultant death. A step by step correlation of the autopsy findings with circumstances became possible.

2. CASE REPORT:

2.1. Brief Story and Crime Scene Details:

According to the police information, a telephonic message was received at the police control room in nearly midnight from some unknown source, regarding a human skeleton lying within an under-construction building on a highway, at a dubious location. The building's owner (traced later) denied of any construction work in the same from nearly past two years. The police reached the spot within an hour or so and inspected the building which was almost in ruins, lacking any electricity. On continued search with the torch-light, the police noticed a skeletal mass lying within a small dark room, devoid of any gate or windows (fig. 1).



Fig. 1: Crime Scene Photograph: Skeletonized Male body within the dark room of a ruined building (night view). The floor of the room is cluttered with bricks, plastic bottles, garbage and other construction material.

On further inspection, the skeleton was found to be heavily smudged with thick layers of mud and foreign matter. Soft tissues were lacking over upper half of the body that was largely skeletonized while the lower half was clad in formal pants.

The floor of the room was cluttered with multiple bricks as of construction material, plastic bottles and thick layers of brownish moist mud. The walls and ceiling of the room were intact with cemented bricks stacked in layers. The police additionally noticed some faint-reddish, drop-like stains extending from near the body up to the entrance of the room. Unsure of their origin, however, no suspicion of any criminal activity was raised.

Finally, the investigation officer attributed the death to some unknown natural disease or fatal insect bite and took the body to the civil hospital for postmortem examination by a board of Medical Officers. The body was initially kept there for additional 48 hours for identification purposes; that was, however, unsuccessful. On account of advanced skeletonization and putrefaction of the body, the doctors referred the case to a higher center for autopsy by forensic medicine specialist, to ascertain the cause of death. The body arrived at the forensic medicine dep't after about 60 hours of its discovery. After taking available history and perusal of the

inquest papers, crime scene details and photographs, the autopsy was commenced.

2.2. Autopsy Findings:

2.2.1. General External Findings:

The upper half of the body was largely skeletonized and smeared with thick layers of mud at places (fig. 2). The lower limbs were clad in dirty bluish pants with hooks and zip tied and intact in situ and a black leather strapped belt with a white metallic buckle (fig. 3). Soft tissues and viscera were



Fig. 2: Upper half of the body was largely skeletonized and smeared with thick layers of mud.



Fig. 3: Lower trunk and pelvic region with mud stained clothing and exposed bones. Evidence of animal scavenging is present over distal epiphysis of humerus and costal ends of lower ribs (upper rib showing postmortem breakage).

largely missing from the upper half of the body, except for a jumbled up mass of putrefied soft tissues around right scapula and shoulder girdle. Animal scavenging was evident over distal epiphysis of right humerus while costal end of a left rib depicted linear breakage and slight splintering extending from the gnawed margins (postmortem in origin). Feeding and puncture marks of scavengers were also evident over distal shafts of both bones of legs near ankles, and over left scapula.

The soft tissue remnants and ligaments surrounding the joints were mummified with cord-like hardening at places. Rest of the ribs, complete left upper extremity, and right forearm with hand, and feet were missing. Mandible was separate and intact. Pelvic region, thighs and legs were mummified and largely intact, with leathery brownish soft tissues while the axial skeleton was lying exposed. External genitalia, typical of male, were well identifiable.

2.2.2. Injuries:

During inspection of the skull, three depressed regions, two evident and one faintly visible, were noticed anterior to bregma and right parietal regions, respectively, and were covered with thick layers of mud (fig. 4).



Fig. 4: Three mud-smeared depressed regions were noticed over the skull; two over frontal bone, in front of bregma and one over right parietal region.

The skull and the rest of the muddy body were thoroughly washed and cleaned under gentle stream of water. The examination of skull leads to an unremarkable disclosure. Three DSFs and a dent, of varied sizes albeit similar features, were present near the vertex region of skull (fig. 5), as follow:

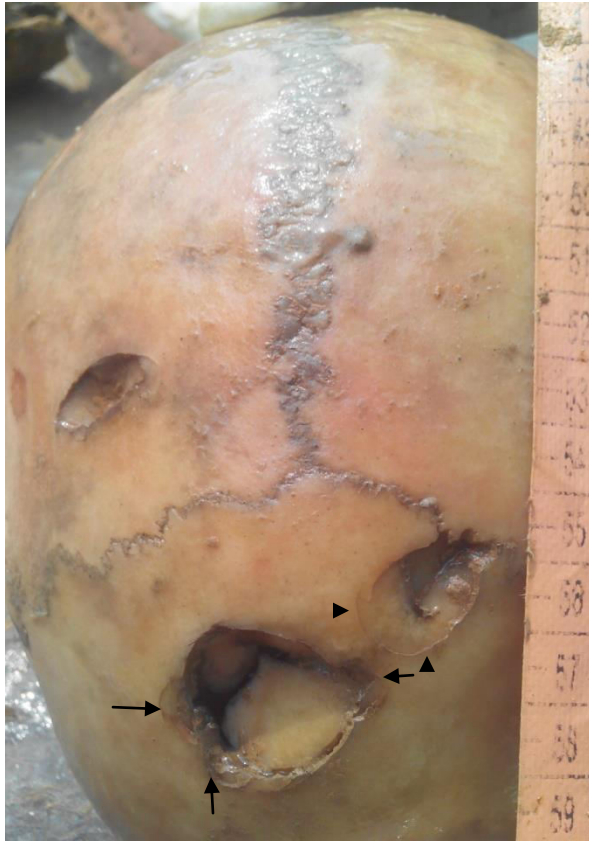

Fig. 5: Skull after cleaning: Three depressed fractures are clearly visible in the regions corresponding to fig. 4. All the fractures are located above hat brim line. One dent (impression) was present over right-lateral midparietal region (not visible here). Terracing is visible over fracture's margins from compression of bone plates (black arrows). Wedge-shaped bone plates are going in. Hoop fractures are visible (arrow head).

- (a) An oval DSF of 2.5 cm x 2.3 cm, over the frontal bone situated 2.5 cm below the bregma and almost symmetrically across the midline. The central part showed maximum depression and measured 8 mm in depth from ectocranial surface. Multiple depressed, chip-like fragments, some arranged radially in a stair-step like pattern (fig. 5), were attached over the margins; two such areas were present along the right lateral margin while one was seen within left margin, consistent with the terracing phenomenon.

Significant crushing of the margins was well appreciable. Wedge-shaped plates of bones, resulting from secondary and tertiary fractures from the central depressed point (of max. impact), were directed within cranial cavity. A linear fracture was radiating from the lateral margin, near a V-shaped area. Inner table of the skull was fractured and depressed in a similar fashion, measuring 7 mm in depth from endocranial surface to the centre, and flaking with exposure of diploë (fig. 6). The fractured tips were acutely jagged. Inner table beveling was present along circular margins.

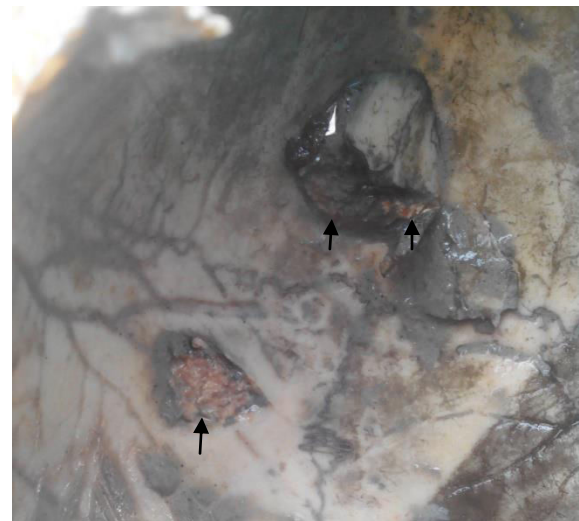

Fig. 6: Inner table showing pyramid shaped bone fragments with jagged tips, directed deep into the cranial cavity. Cortex has been delaminated in some regions (black arrows) exposing skull diploë. Inner table beveling is present within circular fractures

- (b) A pear-shaped DSF of 1.8 cm x 1.5 cm, over the left side of frontal bone, situated 1 cm lateral to injury no. 1, 1.5 cm away from bregma and running in a 7 to 1'O clock direction (fig. 5). The lateral and most depressed zone was merging with the coronal suture. Pyramid shaped bone plates with jagged tips were projected within the cranial cavity. Depth was measured as 4 mm from endocranial surface. Circular arcs/hoop fractures were surrounding anteromedial aspects. Two faintly visible radiating fractures were emanating in a branching fashion from a common base, from the most medial arc of the wound, approaching towards lateral margin of injury no. (a). The upper one of them was faintly arrested onto the radiating fracture of injury no. (a) (fig. 7); thereby suggesting that this injury (b), came after injury no. (a) [Puppe's rule].

- (c) A nearly D-shaped DSF of 1.8 cm x 0.8 cm x 4 mm, over the right parietal bone, situated 2.5 cm lateral to anterior third of sagittal suture and 3 cm behind right-middle of coronal suture. Margins were well crushed with small bony chips clinging loosely over them. Wedge-shaped bony plates were directed-in.

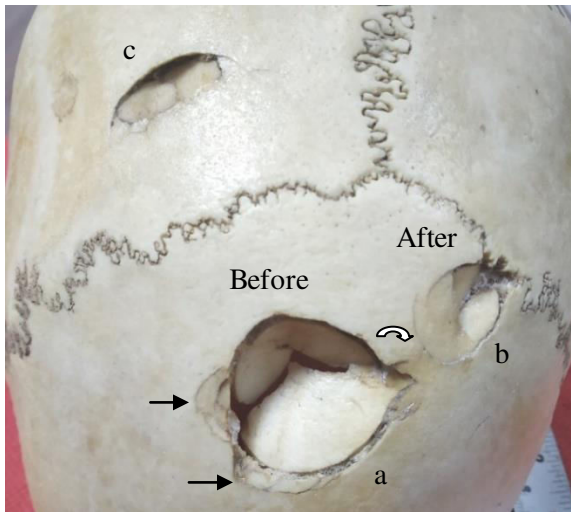


Fig. 7: Processed Skull showing fine and detailed view of the fractures: A linear fracture radiating from injury no. (b) was arrested on (curved thick arrow) a fracture radiating from margins of injury no. (a). Stair-step patterning/terracing (black arrows) and wedge-shaped bone plates with circular and hoop fractures are clearly visible (Injury no. (a), (b), & (c)).

Inner table was apparently non-deformed and non-depressed, but with flaked-off cortex and exposure of diploë (fig. 6).

- (d) An oval indentation of 1 cm x 0.5 cm was present over right parietal eminence (fig. 8). Central portion was dented inwardly and a linear acute groove was running transversely from its posterior margin. No true fracture line or any evidence of healing was seen.




Fig. 8: Dent (impression) over lateral right mid-parietal region of skull (injury no. (d)).

The margins of injury no. (a) to (c) were stained dark with hemorrhagic infiltration of blood into bony trabeculae, suggestive of their acute nature. All the fractures (including the dent) were situated well above hat brim line (HBL).

The lax and collapsed dura mater showed an irregular tear corresponding to injury no. (a). The brain had been putrefied into pasty grayish mass but was skimmed over with little dark hemorrhagic material over the top. No injuries were seen over rest of the bones. Toxicological analysis of the femur, portion of thigh muscle and soft tissue remnants resulted negative for any common poison, drug or alcohol.

The age findings were calculated from the dental charting and tooth attrition, fusion of long bones epiphysis, pubic symphysis face, iliac auricular surface and trabecular pattern of humeral and femurs heads, and were depictive of a young adult individual. The skeletal characteristics were typical of a male. The stature was estimated using vertex pubis length, available skeletal length and multiplication factors as suggested for various long bones of North Indian population.

2.2.3. Opinion:

After considering the crime scene findings and police details, the cause of death was given as multiple injuries to the head, causing a fatal craniocerebral trauma. The injuries were antemortem in nature and caused by some heavy/hard blunt object(s). The manner of death was given as homicidal. The dead body belonged to a young adult male individual, of age ranging between 20 to 30 years, and with a stature measuring 170 cm \pm 8 cm.

2.3. Subsequent police investigation and opinion:

Later on, the alleged weapons of offence were presented by the police to the doctors that were in the form of two reddish-gray construction bricks that were diffusely layered with mud and sand stains (fig. 9). The corners were broken while the surfaces were rugged and bumpy. The weights measured 800 gm and 1600 gm, respectively. After thorough examination of each brick and correlating them with the injuries' details in the PMR, the opinion was given in favor of infliction of injuries and subsequent death by such type of heavy blunt object(s).

Four accused had been traced and arrested, including one juvenile (17 years old) and three adults. As per police theory, they had arranged a meeting with the victim during a late night in that building, in order to settle some monetary dispute. The victim had come with money in-cash, amounting nearly Rs. 30-40,000/- that he had debt from them long back but was agreeing to pay back only on certain grounds. The

victim did not submit to their arguments and the perpetrators tried to snatch money from him. In this heated atmosphere



Fig. 9: Alleged weapons (bricks) brought for forensic medical examination and opinion to correlate with the injuries and death.

the violence escalated which was followed by picking-up of bricks from the local clutter that was lying on the floor. The victim was given multiple hits over the head. The perpetrators fled away with the money.

The deceased was a 26 years old man and, in collaboration with the perpetrators, had previous criminal records in the form of thefts, eve teasing and online financial frauds. The incident took place about 22 days before corpse's discovery.

3. DISCUSSION:

Blunt force trauma is the most common injury found in autopsies. Skull fractures are the most frequent and show most likely association with fatal injuries to the victim.³ The head is often the target of blunt force trauma in assaults. Understanding the etiology of cranial trauma patterning is therefore essential to forensic investigation.

Fracture pattern characteristics depend upon the extrinsic factors like magnitude, area, and duration of the blow, as well as the intrinsic factors such as the ability of the bone to absorb the blow, elasticity, plasticity, and density of bone.⁴ Blunt trauma to the skull can create multiple types of fractures such as linear, depressed, concentric, and hole-type etc.; depending upon the speed and shape of the object used.

The speed, at the moment of weapon's strike, is a strong determinant of the type and shape of resulting fracture. A high

velocity impact over the skull, caused by a small surface weapon such as a hammer, wrench or a rock/stone, may create a DSF that may also reflect the profile of the impacting weapon. Multiple cranial injuries are more frequently associated with violent events than a single cranial injury while discovery of multiple DSFs is strongly suggestive of homicidal blows to the head.^{5,6}

3.1. Rule of Hat Brim Line (HBL):

For the differentiation between violent assault (e.g., a blow to the head with blunt object) and accidents (e.g., a fall), the hat brim line (HBL) rule has been proposed as an important criteria in many forensic pathology textbooks.^{7,8} The HBL corresponds to the maximum circumference of the vault, demarcated by an imaginary line that binds the frontal eminence, the parietal eminence and the external occipital protuberance. The lesions above HBL are more frequent in blow rather than in fall injuries.

Fracasso and colleagues added that blunt force injuries from falls have to be considered below the HBL if the following conditions are fulfilled: (a) Body in standing position before fall (b) Fall from one's own height (c) Flat floor (d) Absence of intermediate obstacles.⁹ An injury from a blow, otherwise, may be suffered anywhere on the head, irrespective of the HBL.

In this context, the analysis of skeletal remains demands special attention and precaution, particularly before allocating the site of fracture to the site of impact. The site and course of linear fractures may not necessarily be the representative of site of impact, due to their frequent formation in the peripheral areas of skull's out-bending, followed by variable courses which are directed by the buttressing and other properties of skull.^{10,11} In contrast, the bone impressions and DSF are always localized at the point of impact where the head is struck with an object having a relatively small surface area.⁸

Following the HBL rule and in discriminating falls from the blows, Guyomarc'h et al did not find any DSF in fall-related fatalities (from standing height or falling downstairs) while all such victims (with DSF) belonged to the category of homicidal blows to the head (DSF: falls-0%, blows-100%). A statistically significant difference was also found in comminuted skull fractures (blows-80%, falls-20%).¹² In a study by Lefèvre et al, DSF in homicides reached 37%, whereas no depressed fracture was observed in either the accidental or sudden death group of falls. The authors suggested that the presence of at least one blunt laceration, one deep contusion and evidence of intracranial trauma is highly indicative of homicide. However, no statistically significant differences were found between the two groups

(falls versus homicides) based on the type of intracranial injury (i.e., subdural or extradural hematoma, cerebral contusion, subarachnoid hemorrhage, and diffuse axonal injury).¹³

Depressed skull fractures have been frequently described in the archeological specimen, reflective of interpersonal violence in the antiquity.¹⁴ An instance of an isolated DSF, similar to the present case (i.e., involving assault with a brick), has been pictured in a well known textbook of forensic medicine.¹⁵

3.2. Manner of Injury:

It is important mentioning here that before relating a DSF to the homicidal manner of death, a detailed description of the circumstances surrounding death must be taken into account. As such, a deep DSF of the occipital bone sustained during fall downstairs has been reported.¹⁶ Similarly, DSF are common in road traffic and high energy transportation accidents.¹⁷ An accidental collapse of the ceiling or building leads to a dramatic collapse of the skull with multiple comminuted fractures.⁶

Suicidal blunt head trauma is rare but may be encountered in schizophrenics and cases with morbid depression, impulsive and mood disorders. As such, cases of self-inflicted DSFs with the hammers are on record.^{18,19} Such cases are characterized by cluttering of lacerations over typical vertex (anterior third of sagittal suture) region of the scalp due to sequential low force impacts, parallel-oriented shallow lacerations in the vicinity which are equivalent to trial injuries, intact brain and dura mater and a shallow nature of DSFs (due to lesser impact force in self-infliction than in an assault).^{18,19} Such incidents have almost invariably occurred within one's own home or at acquaintance's residence.^{15,18,19} The hammer, due to its pendulum-like impact mechanism, of transmitted inertia via long handle to a heavy terminal head, can expectedly result in such self-sustained blows with DSFs, especially over the vertex of head; which is unlikely with a broad-small object, such as a brick in the present case. The impact forces and the resulting fractures from cranial blows with shaped and patterned surface objects have been well-studied.^{6,11,20,21}

Polson and Gee have mentioned two interesting cases of self-inflicted head injuries by small axes: in one of them the skull was almost carved all over the vault with wedge shaped sharp defects, all running in a parallel plane while in the other case, multiple shallow, score-like vertical and parallel grooves had formed on the posterior parietal and occipital regions. The former victim had finally killed himself by inflicting a stab wound in the heart.¹⁵

On contrary, multiple localized DSFs, especially those belonging to the signature or tool-mark variety and located above the HBL, running in different planes, lacerating the dura mater and brain and in a body found at some clandestine location, such as in the present case, are strongly indicative of a homicidal assault.

3.3. Cause of death (in acute cases):

Severe blows to the head with blunt instruments are known to cause fatal DSFs with associated fracture-lacerations of the brain, cerebral contusions beneath the location of the blow, as well as the intracerebral hemorrhage.²² Death from exsanguination and haemorrhage in suicidal cases has been attributed to the breach of superior sagittal sinus, due to typical location of the lacerations and DSFs over sagittal suture while the brain and dura mater are largely intact in such cases.^{18,19}

As such, the distances between the endocranium and the pial surface of brain have been measured in cadavers that were found ranging from 3.5 mm to 6.7 mm in a parasagittal plane,²³ which was possibly surpassed in the present case (esp. injury no. (a), with laceration of dura mater), causing injury to the meninges and brain. The involvement of superior sagittal sinus would have most likely caused a lethal hemorrhage.¹⁹

3.4. Mechanism of Blunt Cranial Trauma:

The site of the maximum depression within the fracture signifies the locus of impact with the wedge to pyramidal-shaped plates of bones commonly turning inwards, circumscribed by the arc-like circular or hoop fractures. Such tertiary fractures in blunt trauma are internally beveled.⁴ The presence of adherent bone flakes at the fracture site is suggestive of an intact periosteum and soft tissues when the trauma was inflicted, i.e., a fleshed bone.²⁴ Additionally, when the fresh bone bends, divisions are created between the diploë and the tables, which usually produce beveled fractures on the inner table (beveling) and a detachment of the outer table (delamination).²⁵ The perimortem fractures depict acute or obtuse angled margins in contrast to the postmortem ones in which they run perpendicular to the bone surface.²⁶

A localized DSF involves dynamic crushing mechanism and, especially with a flat-round surface object, frequently shows lack of secondary radiating or relief fractures over the margins.²⁷ The shape and size of the inflicting weapon/object is often mirrored in the fracture, thereby assisting in tool-mark analysis.²⁷ Such tools have been classically related to a cross section of 4 cm x 4 cm. Additionally, after application of

significant force, if the area of skull impact is small (<13 cm²), it predominantly leads to complete penetration in the form of a hole or DSF while if the contact area is large (>13 cm²), a perforation of the skull rarely occurs.⁸ The sequence and number of blows may be gained from the Puppe's rule, i.e., a fracture initiated from a second blow will not cross a previous fracture.²⁸ It is important to ascertain the site of impact as well as the nature and course of fracture before applying this rule to a fractured bone.

It is also worth mentioning that a careful analysis of the margins of a DSF may reveal terracing or a stair-step like pattern in which tiny to moderate sized chips of bones may be clinging loose and directed inwardly in a radial pattern, due to compression of outer tables of skull (concentric terracing). Terracing may be symmetrical or asymmetrical depending upon the angle of strike, although commonly seen in angled blows to the skull.^{8,15,29} Comminuted fractures are formed at the inner table, and the resulting pyramid-shaped splinters project into the interior of the skull, usually perforating the dura mater and lacerating the subjacent brain.⁸

If only limited force is applied, the DSF can be restricted either to the outer or the inner table. The outer table may either flake-off or bent inwardly leading to a dent (fracture!) due to superficial indentation of the outer table while detachment with an inward displacement of the bone fragments may occur from the inner table leading to an exposure of skull diploë.³

With multiple blunt traumas, plates of bone formed by radiating and concentric fractures may exhibit 'knapping' or flaking along the fracture margins with evident plastic deformation of the skull.³⁰ Repeated blows to an area of shattered bone may force bone segments shard in such a way so as to flake their margins. The presence of knapping may indicate multiple blows. In addition, delamination along the diploë is sometimes present with multiple blows.⁴

From the overall fracture pattern and appearances, an assessment may be made whether the blows were given on a fixed or the moving head.^{3,6,21}

4. CONCLUSION:

Contrary to what happens when dealing with a well preserved cadaver, data available on skeletal material rarely allows the precise reconstruction of a lethal event, although signs of trauma may persist in bone and strongly suggest foul play. Through careful reconstruction and examination of the fracture patterns and appearances, useful information regarding the circumstances surrounding death, characteristics of trauma, and the cause and manner of death

can be gained at autopsy. A bone may be the only 'tell-tale' evidence of a violent and murderous event.

- **CONFLICTS OF INTEREST STATEMENT:** The authors declare that there are no possible conflicts of interest.
- **SOURCE OF SUPPORT/FUNDING:** Nil
- **ACKNOWLEDGEMENT:** Nil

REFERENCES:

1. Flieger A, Kölzer SC, Plenzig S, et al. Bony injuries in homicide cases (1994-2014). A retrospective study. *Int J Legal Med.* 2016;130(5):1401-8.
2. Bhadra P, Hart AJ, Hall MJ. Factors affecting accessibility to blowflies of bodies disposed in suitcases. *Forensic Sci Int.* 2014;239:62-72.
3. Moritz AR. *Pathology of Trauma*, 2nd ed, Lea & Febiger, Philadelphia, 1954.
4. Berrymann HE, Symes SA. Recognizing gunshot and blunt cranial trauma through fracture interpretation. In: Reichs K (Ed.), *Forensic Osteology. Advances in Identification of Human Remains*, 1st ed., CC Thomas, Springfield, Illinois, 1998, pp. 333-52.
5. Delannoy Y, Becart A, Colard T, et al. Skull wounds linked with blunt trauma (hammer example). A report of two depressed skull fractures—elements of biomechanical explanation. *Leg Med (Tokyo).* 2012;14(5):258-62.
6. Kranioti EF, Grigorescu D, Harvati K. State of the art forensic techniques reveal evidence of interpersonal violence ca. 30,000 years ago. *PLoS One.* 2019 3;14(7):e0216718.
7. Dettmeyer RB, Verhoff MA, Schütz HF. *Forensic Medicine: Fundamentals and Perspectives*, 1st ed, Springer-Verlag, Berlin, Heidelberg, 2014.
8. Meissner C, Oehmichen M. *Forensic Neuropathology.* In: Madea B (Eds). *Handbook of Forensic Medicine*, 1st ed, Wiley-Blackwell, NJ, USA, 2014, pp. 283-313.
9. Fracasso T, Schmidt S, Schmeling A. Commentary on: Kremer C, Racette S, Dionne CA, Sauvageau A. Discrimination of falls and blows in blunt head trauma: systematic study of the hat brim rule in relation to skull fractures. *J Forensic Sci* 2008; 53(3):716-9. *J Forensic Sci.* 2011;56(6):1662; author reply 1663.
10. Gurdjian ES, Webster JE, Lissner HR. The mechanism of skull fracture. *Radiology.* 1950;54(3):313-39.
11. Isa MI, Fenton TW, Goots AC, et al. Experimental investigation of cranial fracture initiation in blunt human head impacts. *Forensic Sci Int.* 2019;300:51-62.

12. Guyomarc'h P, Campagna-Vaillancourt M, Kremer C, et al. Discrimination of falls and blows in blunt head trauma: a multi-criteria approach. *J Forensic Sci.* 2010;55(2):423-7.
13. Lefèvre T, Alvarez JC, Lorin de la Grandmaison G. Discriminating factors in fatal blunt trauma from low level falls and homicide. *Forensic Sci Med Pathol.* 2015;11(2):152-61.
14. Murphy MS, Gaither C, Goycochea E, et al. Violence and weapon-related trauma at Puruchuco-Huaquerones, Peru. *Am J Phys Anthropol.* 2010;142(4):636-49.
15. Polson CJ, Gee DJ. Injuries to specific regions. In: Polson CJ, Gee DJ, Knight B (Eds). *Essentials of forensic medicine*, 4th ed, Pergamon Press, Oxford, New York, 1984, pp. 148-95.
16. Case MES. Central nervous system trauma. In: Nelson JS, Mena H, Parisi JE, Schochet SS (Eds). *Principles and Practice of Neuropathology*, 2nd ed, Oxford Univ. Press, NY, 2003, pp. 140-75.
17. Lumb DP, Whitwell HL. Adult Skull Fractures. In: Whitwell HL (Eds). *Forensic Neuropathology*, 1st ed, Hodder Arnold, New York, 2005, pp. 53-61.
18. Park H, Lee B, Yoon C. Suicide by blunt head trauma - Two cases with striking similarities. *Forensic Sci Int.* 2015;255:102-5.
19. Kim SW, Putzke M, Uhl E, et al. Self-Inflicted Hammer Blows to the Cranial Vault: An Interdisciplinary Challenge. *Prim Care Companion CNS Disord.* 2016;18(3):10.4088/PCC.15br01927.
20. Ramsthaler F, Kettner M, Potente S, et al. Hammer blows to the head. *Forensic Sci Int.* 2019;301:358-370.
21. Ruchonnet A, Diehl M, Tang YH, et al. Cranial blunt force trauma in relation to the victim's position: An experimental study using polyurethane bone spheres. *Forensic Sci Int.* 2019;301:350-7.
22. Fenton TW, deJong JL, Haut RC. Punched with a fist: the etiology of a fatal depressed cranial fracture. *J Forensic Sci.* 2003;48(2):277-81.
23. Fournier M, Combès B, Roberts N, et al. Mapping the distance between the brain and the inner surface of the skull and their global asymmetries. *Medical Imaging 2011: Image Processing*, Feb 2011, Orlando, United States. pp.79620Y.
24. Kranioti, E. Forensic investigation of cranial injuries due to blunt force trauma: Current best practice. *Res Rep Forensic Med Sci.* 2015;5:25-37.
25. Berryman H, Haun S. Applying forensic techniques to interpret cranial fracture patterns in an archaeological specimen. *Int J Osteoarchaeol.* 1996;6:2-9.
26. Walker PL. A Bioarchaeological Perspective on the History of Violence. *Ann Rev Anthropol.* 2001;30(1):573-96.
27. Kimmerle EH, Baraybar JP. *Skeletal Trauma: Identification of Injuries Resulting from Human Rights Abuse and Armed Conflict*, 1st ed, Boca Raton, CRC Press, Taylor & Francis Group, 2008.
28. Madea B, Staak M. Determination of the sequence of gunshot wounds of the skull. *J Forensic Sci Soc.* 1988;28(5-6):321-8.
29. Saukko P, Knight B. *Forensic Pathology*, 4th ed, Boca Raton, Taylor & Francis Group LLC, 2016.
30. Klepinger LL. *Fundamentals of Forensic Anthropology*, 1st ed, New Jersey, Wiley-Liss, 2006.